

# Emerging Technology in Vitreoretinal Surgery

## Three key predictions about the future of small-gauge vitrectomy

**CHRISTOPHER D. RIEMANN, MD**

Modern vitreoretinal surgery is simply inseparable from cutting-edge technology — pun intended. From some of the earliest innovations in applied medical optics, such as slit lamps, binocular indirect ophthalmoscopes, and argon laser, all the way to today's vitrectomy machines, swept-source OCT, and bionic retinal prostheses, modern vitreoretinal surgery has always pushed the development of biomedical technology, and advances in technology have always driven advances in vitreoretinal surgery.

For those of us who have been in practice for more than 15 years, it is interesting to reflect on our training and how we currently do very little in the way that we were taught. The Practices and Trends Survey, conducted by the ASRS, has shown us that small-gauge, trocar-based pars plana vitrectomy is here to stay and has almost completely replaced 20-gauge surgery.

Vital dyes are routinely used to stain the vitreous and aid with membrane peeling. Noncontact wide angle viewing has become routine. OCT is indispensable in the clinic and is the standard of care for a large percentage of patients. We are all on the verge of repetitive motion injuries from injecting intravitreal medications. Things have changed indeed.

An important driver for this change has been developing technology. By our very nature, many of us are techies at heart, and we anxiously await the newest smartphone, tablet computer, automotive innovations, and of course, the newest, latest, and greatest technology to help us care for our patients.

Christopher D. Riemann, MD, practices with the Cincinnati Eye Institute in Ohio. He reports financial interests as a consultant to Alcon, Haag-Streit, and MedOne. Dr. Riemann can be reached via e-mail at [Criemann@cincinnatieye.com](mailto:Criemann@cincinnatieye.com).

There are three emerging technology trends in vitrectomy surgery I'd like to discuss in this piece.

- We have very substantively improved our understanding of the importance of “sphere of influence” (SOI) at the tip of the vitreous cutter for both efficient and safe vitrectomy. Next-generation cutter technology is evolving in a way that will allow us to leverage these physical principles to the benefit of our patients. Twenty-seven-gauge surgery and ultrahigh cut rates are key emerging technologies that will be mainstream in a few short years.
- Next-generation microscopy will dramatically enhance surgical viewing by integrating machine vision, digital imaging, and pre- and intraoperative testing into the surgical microscope.
- Cost concerns are leading to innovations on the part of equipment manufacturers and new paradigms regarding how to maximize efficiency.

### *SPHERE OF INFLUENCE*

In cataract surgery, much is made of followability, which relates to the phacoemulsification probe’s ability to draw in lens material. Followability is generally considered a good thing by phaco surgeons. However, as soon as a cataract surgery is complicated by the presentation of vitreous, that very same followability immediately turns into a liability. Continued aspiration with the phaco probe draws in vitreous and can create unwanted vitreous traction and its adverse anatomical side effects, a call to a vitreoretinal colleague, and an unhappy patient.

In the posterior segment, vitreous is almost always present, and vitreous followability is a terrible thing. From the earliest days of vitrectomy, the vitreous cutter was used to reduce vitreous traction by interrupting suction with a cutting port and removing the vitreous in discrete bites. SOI — or the cutter port’s ability to draw in material — was born. Although cut rates rapidly progressed beyond the 1 cps of Dr. Machemer’s vitreous infusion section cutter, most 20-gauge vitreous surgery used reduced vacuum to limit SOI and vitreous traction. A few systems used flow control. As transconjunctival small-gauge systems became available, much smaller cutter port geometry reduced SOI in a way that presented new challenges and new opportunities.

Smaller cutter port geometry and narrower lumens ([Table](#)) made early 25-gauge surgery painfully slow. We have all learned Poiseuille’s law and know that flow through a tube is roughly proportional to the fourth power of the internal diameter, so it was no surprise that flow rates and vitreous removal were less efficient with first-generation 25-gauge instrumentation.

<b>Table. Representative Vitreous Cutter Geometries by Gauge</b>			
<b>GAUGE</b>	<b>INTERNAL DIAMETER (MM)</b>	<b>PORT DISTANCE FROM TIP (MM)</b>	<b>PORT SIZE (MM<sup>2</sup>)</b>



20	0.52	0.43	$0.53 \times 0.30 = 0.16$
23	0.39	0.25	$0.40 \times 0.18 = 0.07$
25	0.29	0.23	$0.32 \times 0.14 = 0.045$
27	0.20	0.23	$0.29 \times 0.12 = 0.035$

SOURCE: DUTCH OPHTHALMIC RESEARCH CENTER

However, with this downside came an upside. Small-gauge cutters proved to be extraordinarily versatile on the retinal surface. The reduced SOI of small gauge cutters allowed surgeons to perform more segmentation and delamination with the cutter alone. Peripheral vitrectomy over detached retina became more controlled, but efficiency remained a rate-limiting factor. Ultrahigh cut rates have solved this problem and have reinvigorated small-gauge surgeons.

### Vitreous Is Different

It is true that a 50% reduction in vitreous cutter lumen diameter will reduce the flow of balanced saline solution by a factor of 16 (diameter to the fourth power). However, the story in vitreous is more complicated. The viscosity of undisturbed vitreous in vivo, is approximately 500 to 2,000 cSt. The viscosity of BSS is 1 cSt. Undisturbed formed vitreous is essentially impossible to aspirate through a small-gauge probe with suction alone. The cutter port becomes clogged with vitreous gel. The viscosity of uncut vitreous is not relevant in most discussions of vitreous cutter performance because we (hopefully) never aspirate uncut gel.

The fluid dynamics of the vitreous cutter are defined by the concept of slug flow. Slug flow describes the flow of liquid suspensions — or fluids with chunks of matter floating in them. At a very low cut rate, the viscosity of the vitreous cutter aspirate looks more like that of uncut vitreous, but as the size of the suspended vitreous clusters decreases, the effective viscosity of the suspension approaches that of the carrier solution.

The key point here is that the flow of a suspension improves as the size of embedded chunks of matter (in this case vitreous) decreases. Put another way, higher cut rates reduce the size of the suspended vitreous clusters. As vitreous cluster size decreases, vitreous cutter flow and the efficiency of vitreous removal increase.

Until quite recently, all vitrectomy machine systems employed a single pneumatic drive spring return cutter design. These cutters used a pneumatic pulse to close the cutter guillotine blade and relied on a spring to open it back up to complete the cutter cycle. The limitation of this technology was that, as the cut rate increased, duty cycle (or cutter port percentage of open time) decreased, creating a frustrating Catch-22 for surgeons and vitrectomy machine engineers alike.

The improved vitreous removal efficiency of higher cut rates was dramatically limited by the diminished duty cycle inherent with these cutters at these higher cut rates. This phenomenon was defined as “port limited flow,” and it substantially limited the utility of increasing cut rates. As cut rate increases, vitreous removal becomes more efficient until duty cycle degrades to the point at which the open port time is so short that nothing happens at the cutter tip — even at maximal vacuum.

### **Recent Developments**

Engineering innovations have recently enabled vitreoretinal surgeons to employ very high cut rates with a preserved duty cycle. The “dual pneumatic drive” design of the Alcon (Fort Worth, TX) Constellation vitrectomy system eliminates the rate-limiting passive spring return phase of the cutter by replacing the spring with a second pneumatic piston that actively pushes the guillotine blade back into the open position. This provides excellent duty cycles at cut rates of up to 7,500 cpm — and possibly even higher.

The “twin duty cycle” cutter design by DORC (Exeter, NH) eliminates port closed time by having a cutting port drilled into the closed guillotine blade that allows for a second vitreous cut on the upstroke of the cutter.

The relative advantages and disadvantages of these two approaches relative to one another remain to be elucidated and are beyond the scope of this piece. The important point is that the problem of ultrahigh cut rates with preserved duty cycle has been solved.

### **Smallest Gauge Yet**

The key emerging development in vitrectomy surgery is the combination of 27-gauge cutter geometry (with a superlimited SOI) with superb vitreous cutter efficiency due to ultrahigh cut rates — in the range of 7,500+ cpm, with a preserved duty cycle. These systems allow for unprecedented access to small tissue planes on the retinal surface, while also allowing for efficient, safe, and complete core and peripheral vitrectomies.

Shaving the vitreous base over detached retina is much more controlled. Aggressive focal application of vacuum right on the retinal surface greatly facilitates elevation of the posterior hyaloid and allows the 27-gauge vitreous cutter to be used as an active pick. Complex diabetic tractional retinal detachment repair and fibrovascular membrane removal are possible with the cutter alone, greatly reducing the need for bimanual dissection in even the most challenging cases of



diabetic retinopathy. The 27-gauge cutter has evolved into an extremely versatile multifunction tool.

A surgical technique adjustment is necessary to fully realize the full benefit of next-generation 27-gauge surgery with ultrahigh cut rates. The cutter port is superbly efficient at dispatching anything that is presented to it, but — because of its reduced SOI — it will not draw vitreous (or anything else) into the cutter port to be cut. The surgeon must proactively place the cutter port into the precise location where its action is needed.

The cutter port must always face the gel during peripheral vitrectomy. Peripheral gel will not be removed unless the cutter port is where it needs to be. Gently placing the actively cutting and aspirating cutter tip right onto the surface of the retina is a beautiful thing.

### *NEXT-GENERATION MICROSCOPY*

There are two emerging technologies that fall under the heading of next-generation microscopy. Digital microscopy will transform the operative microscope into an integrated surgical platform that will provide visual information to the operating surgeon in ways never before imagined. Intraoperative OCT will be integrated into the microscope and will provide indispensable information to the operating surgeon.

### **An Anecdote**

Some time ago, I had the pleasure and privilege of working with some colleagues in a developing nation. We planned to see a full day's worth of patients at a local eye clinic. At the beginning of the day — after a tasty breakfast — I walked into the clinic space and was aghast when I saw the slit lamp we would be using. It was a Haag-Streit (Mason, OH) cast iron slit lamp with all of the original optics; it was clean but very old. Its rough unpolished black swing arm clearly had the date 1908 and the word Germany among its markings.

My anxiety began to build. How would I take care of patients? Didn't my colleagues realize that I was trained in the most prestigious institutions and intended to provide the highest level of care possible?

I sat down to examine the first patient and adjusted the oculars to my pupillary distance and instrument myopia settings and noticed that breakfast wasn't sitting so well in my belly anymore. As I looked through the oculars, I was blown away. The view through this ancient slit lamp — this museum piece — was just as good as the view through any slit lamp in my clinic. The day proceeded without a hitch, lunch was delightful, and I had been humbled.

Throughout the day I paid very close attention to the light-collecting ability of this old slit lamp and realized that the optical core of this instrument was functionally equivalent to any modern operating microscope. Of course, there have been great advancements in optics over the past 100 years, but the fact remained that the



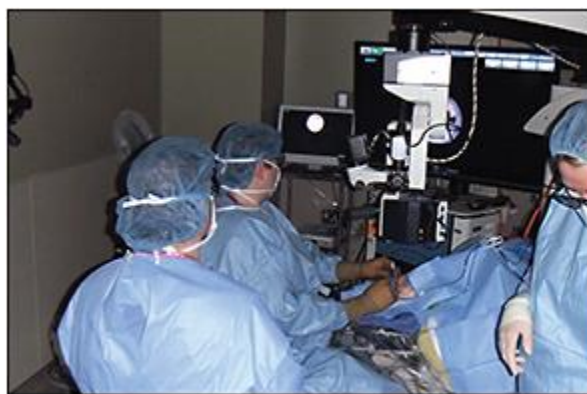view through this slit lamp was perfectly adequate to perform vitrectomy (theoretically speaking, if it was mounted transversely).

### Expanding Vision

For vitreoretinal surgery, as for all other surgical disciplines, much has changed in the operating room over the past 50 years. Why then is the view through the operating microscope functionally the same as through a 100-year-old slit lamp? Why was I using the equivalent of a 78 rpm record when the rest of the OR had evolved through 33 rpm technology, audio CD technology, and MP3 audio compression technologies, and was now streaming music from the cloud?

Of course, this question was ridiculous. Extraordinarily capable technology firms had made huge improvements in operative microscopy. Many of these were on the illumination side of things, and in retinal surgery, as soon as the case gets interesting, the microscope light is turned off. When would improvements in sensor technology, video display technology, and computational speed finally allow the operating microscope to enter the 21st century?

Modern 1,080- and 4,000-pixel display technologies, as well as fast, high, dynamic range cameras, have, for the first time, allowed digital microscopy to enter the vitreoretinal operating room. High-resolution, three-dimensional, high-definition (3DHD) machine vision can be used for ancillary imaging alongside the optical microscope and may even replace direct optical viewing of the surgical field entirely. 3DHD digital imaging can be viewed on a screen, and several surgeons have lauded the benefits of screen-based retinal surgery on the health of the surgeon's cervical spine. I have personally performed "heads-up" screen-based surgery using technology by TrueVision (Santa Barbara, CA), Haag-Streit, Ikegami (Maywood, NJ), Sony (New York, NY), Panasonic (Newark, NJ), and Optronics (Muskogee, OK) ([Figure 1](#)).



**Figure 1. "Heads up" technology in use in the OR.**

Digital imaging can also be overlaid or added to the oculars of the microscope. Whichever form this technology eventually takes, the digital microscope or optical digital hybrid microscope will open a whole new world of possibilities.

Imagine a “cut by the numbers” template projected onto the surgical field. Imagine preoperative OCT volume scans and fluorescein angiographic imaging overlaid onto the surgical view and tracking with movement of the eye.

Imagine adjusting the contrast and gain settings of the cameras to enhance viewing of stained membranes so that lower concentrations of vital dyes might be used for membrane peeling. Imagine real-time instrument tip tracking and real-time feedback about the safety of instrument positioning within the eye, based on intraoperative and preoperative imaging.

Imagine using the enhanced electromagnetic bandwidth of silicone-based sensors (that “see” far into the invisible near-infrared range) to reduce phototoxicity and improve safety. Imagine a “dark” light pipe illuminating the eye in infrared and false-color renderings that are surgically useful.

Imagine a microscope that is integrated into your vitrectomy machine, in which pixels in the surgical field of view relay real-time information regarding the fluidic settings and behavior of the vitrectomy machine. Imagine an integrated surgical cockpit.

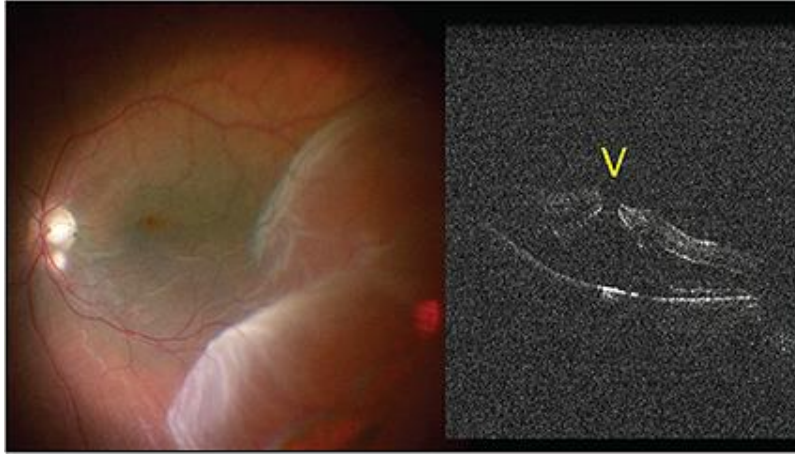
The possibilities are endless. This space is very dynamic and many extraordinarily capable technology firms are genuinely committed to developing next-generation digital microscopy.

### **The Emerging Role of iOCT**

Intraoperative OCT (iOCT) deserves special mention as just one example of how pixels are being employed in the OR. Both Haag-Streit and Carl Zeiss Meditec (Dublin, CA) have developed integrated iOCT units that are currently available in Europe and will be FDA approved soon. This technology does not need to be imagined. It’s here.

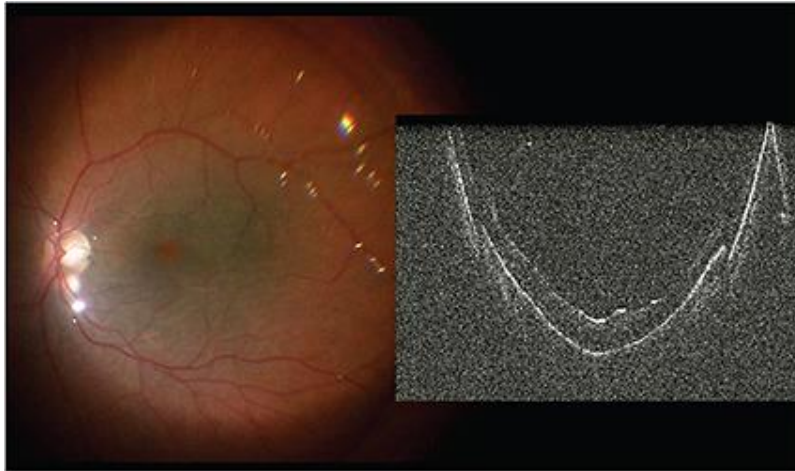
A clinical case utilizing the Haag-Streit iOCT unit perhaps best illustrates the versatility and utility of intraoperative OCT. In this patient ([Figure 2](#)), a full-thickness macular hole has caused a rhegmatogenous retinal detachment. Visual acuity has been 20/400 for the past month. Both the macula-involving detachment and the macular hole are evident clinically and are unequivocally confirmed by iOCT through the direct contact lens.





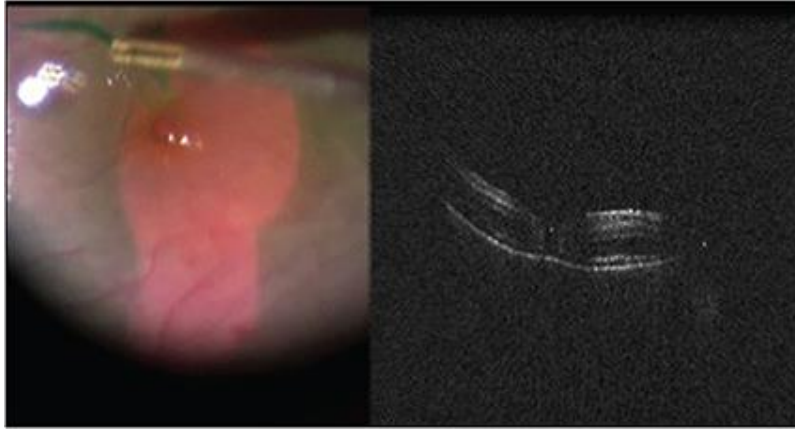
**Figure 2. A full-thickness macular hole causing a rhegmatogenous retinal detachment.**

Under perfluorocarbon, the macula is attached. Note the step-off artifacts from the edge of the perfluorocarbon bubble ([Figure 3](#)). After peeling the internal limiting membrane, the macular hole starts to reapproximate ([Figure 4](#)).



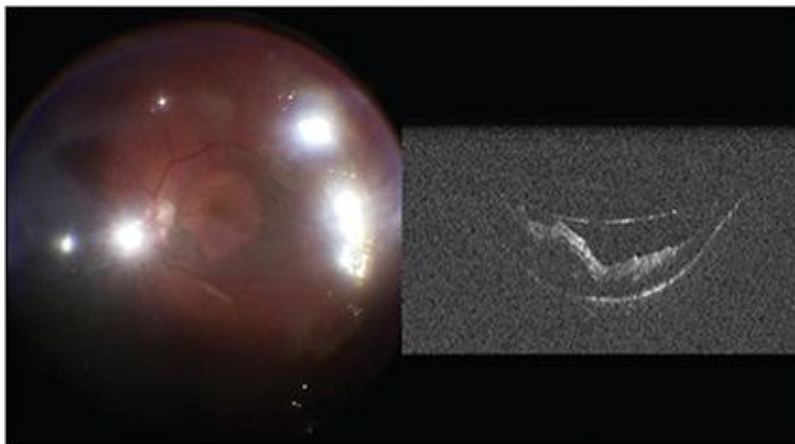
**Figure 3. Under perfluorocarbon, the macula is attached, with step-off artifacts from the edge of the bubble.**






**Figure 4. After peeling the internal limiting membrane, the macular hole starts to reapproximate.**

Following air-fluid exchange, a small amount of subretinal fluid has accumulated under the macula that was not evident clinically. Note the back of the air bubble and a small amount of preretinal fluid, which was also not evident clinically ([Figure 5, page 50](#)).



**Figure 5. Following air-fluid exchange, a small amount of subretinal fluid has accumulated under the macula.**

After carefully drying the macula with a soft-tip cannula, the subsensory fluid is gone, and the macular hole is closed. iOCT imaging provided a precise endpoint for aspiration with the soft tip. This was continued until the hole closed, and all pre- and subretinal fluid was removed ([Figure 6](#)).



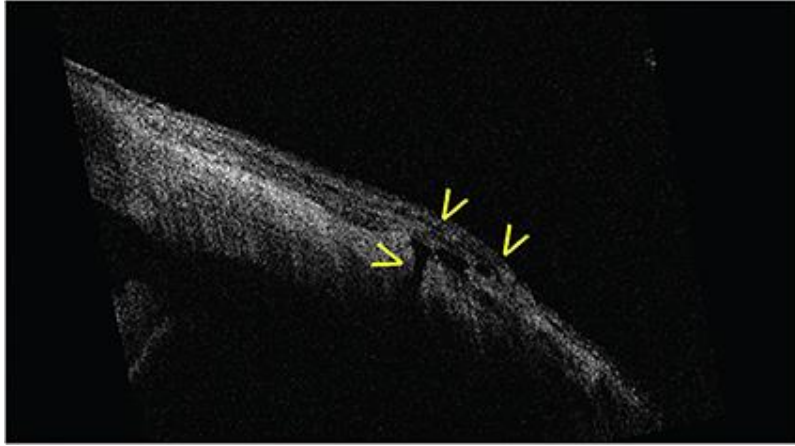
**Figure 6. The hole closed, and all pre- and subretinal fluid was removed.**

This patient recovered 20/60 VA and remained anatomically stable with a closed macular hole and attached retina for more than one year of follow-up. This clinical case beautifully illustrates the robustness of the Haag-Streit iOCT. Excellent images were obtained through vitreous, BSS, and heavy liquids, as well as air. These images informed surgical decision-making in a useful way.

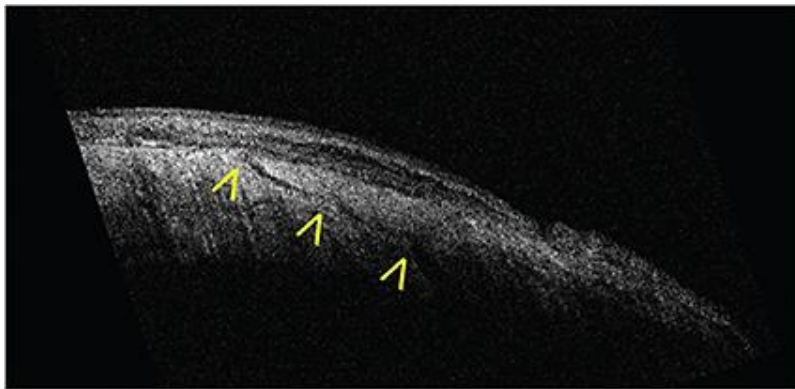
### **Other iOCT Considerations**

iOCT imaging through silicone oil was not demonstrated in this case, but it is also possible and is equally useful. Intraoperative real-time OCT assessment of posterior-segment anatomy may be beneficial in macula-involving retinal detachment repair and macular hole surgery, as well as surgery for patients with vitreomacular traction syndrome and posterior hyaloidal traction syndrome.

Anterior segment iOCT may also be useful for the retinal surgeon. Here, iOCT of the pars plana immediately after trocar cannulas are removed clearly illustrates the rationale for beveled vitrectomy trocar cannula placement. In this image of the pars plana after the cannulas are removed, an open 25-gauge sclerotomy is present with a small conjunctival bleb ([Figure 7](#)). This is in sharp contradistinction to this much more beveled sclerotomy which is closed and does not have an overlying conjunctival bleb ([Figure 8, page 52](#)).



**Figure 7. The pars plana after the cannulas are removed; an open 25-gauge sclerotomy is present with a small conjunctival bleb.**



**Figure 8. With a more beveled sclerotomy, which is closed, there is no overlying conjunctival bleb.**

iOCT that is integrated into the operating microscope is a versatile and powerful imaging modality that holds a great deal of promise for the future. The Haag-Streit iOCT, in conjunction with the Haag-Streit/Möller-Wedel (Wedel, Germany) Hi-R NEO 900 NIR microscope, represents a superb first offering of this technology. I have not personally used the Zeiss offering in this space, but I very much look forward to doing so.

OCT was developed for use in the clinic by David Huang, MD, in the mid-1990s. Retinal surgeons did not fully embrace this technology until a decade later. Today, the thought of caring for clinic patients without OCT is anathema. I believe that iOCT will be considered in the same way in the very near future.

It will enable more precise, more efficient, and ergonomically enhanced vitreoretinal surgery. Once it becomes integrated into next-generation digital microscope technology, we will be shooting live iOCT in a majority of cases and may even operate while looking at superimposed, live, ultrahigh-speed OCT video that is superimposed onto the 3DHD digital surgical field.

## *COST CONCERNS*

We live in a brave new world. The political and economic realities of health care in the 21st century have forced all of us to take a hard look at the cost-effectiveness of what we do. The cost-effectiveness of vitreoretinal surgery is front and center as never before.

While new technology is certainly expensive, vitrectomy system manufacturers are directing a great deal of engineering expertise toward cost containment. There are two approaches to this problem that are currently being employed.

Low cost vitrectomy systems with limited features have a very low per case disposable pack cost and have proved to be functional and reasonable for selected vitreoretinal surgery cases. Some colleagues have even made the foray into office-based vitrectomy surgery.

The other approach has been to engage fiscal challenges with a different kind of engineering expertise. The upfront cost of a vitrectomy machine and the per case disposable pack cost are certainly very important line items in the budget of any OR.

However, the most “expensive” part of running an OR is the personnel cost. Efficient surgery with optimized operating times, very short room turnover, and reliable, predictable machine performance allow the entire OR team, including the front desk, preoperative nursing and nurses’ aides, intraoperative scrub techs and circulating nurses, anesthesia personnel, PACU nurses, and the operating surgeon, to go home earlier. Ten minutes of reduced case time and 15 minutes less turnover time spread out over a 10-case day allows everyone to leave almost four hours earlier. Time certainly is money.

### **More Efficient Equipment**

Efficient sclerotomy trocar blades (eg, EdgePlus trocars from Alcon) that reliably create linear wounds reduce the need to spend additional time suturing. Active intraocular pressure control systems (Alcon) create fluidic control and allow for more aggressive application of vacuum at the cutter tip. Stiffening sleeves allow for efficient movement of the globe, even with 27-gauge surgery.

Intelligent application of the reduced SOI, possible with ultrahigh cut rates and small-gauge surgery, allows for efficient, safe, and precise surgery. A new multivent, side outlet, dual bore cannula design greatly enhances the efficiency and safety of vital dye and heavy liquid injection with small-gauge, closed system, trocar-based surgery (Side-Flō cannula by MedOne [Sarasota, FL]). The list goes on. Surgeons and operating facilities will need to decide which approach is best suited for each surgeon/facility combination and make the choice to implement the technology best suited for each particular fact pattern.



## FINAL THOUGHTS

The clinical practice of retinal surgery has always been challenging, and it is precisely these challenges — and the rewards of meeting them — that draw many of us into this career. The diseases are difficult, and the retinal specialist does an extraordinary and disproportionate amount of the “heavy lifting” in the fight against blinding diseases. The retinal examination is difficult to do well, the testing interpretation is intellectually demanding, and clinical decision trees can be very complex. The unusual  $P < .05$  patient is potentially lurking behind every exam room door.

The practice of retina has been bombarded with more regulatory and compliance burdens, reimbursement cuts, aggressive bundling restrictions, insurance company reimbursement shenanigans, and the forced implementation of EHR technology that is fundamentally not ready for prime time (note that new and improved EHR systems are not part of this piece). Physician satisfaction is at its lowest level in years.

During times of challenge and transition, it is important to step back and remember why we do what we do. Employing the latest and greatest technology to benefit patients has always been and will always remain an important source of gratification and fulfillment for the retinal surgeon. Advancing technology will sustainably help us to take better care of more diseases in greater numbers of patients with better outcomes. From this perspective, there has never been a better time to be a retinal surgeon. **RP**

---

*Retinal Physician*, Volume: 11 , Issue: November 2014, page(s): 45-52